

**PATIENT**

Jules Hudson

SPECIES

Feline

BREED

Sphynx

SEX

Female Intact

AGE

5 years

WEIGHT

8.4lbs

INTERPRETED BYMaggie Machen Lamy,
DVM, DACVIM
(Cardiology)**IMAGING PERFORMED BY**

Sarah Pender, CVT

HOSPITAL NAME

SVS Imaging QC

REFERRING VET

Dr. Narske

INVOICE

29783

DATE

3/22/23

PRESENTING CLINICAL SIGNS

History: Baseline echo. Doing well at home.

ECHOCARDIOGRAM FINDINGS

2D, m-mode, color flow and doppler imaging is available. The left ventricular wall is normal in dimension. There is a diffusely hyperechoic endocardium consistent with mild fibrosis. The papillary muscles are normal in size and hyperechoic. The endocardium appears normal. The left atrium is normal in size. The right atrium is normal in size. The right ventricle appears normal. The mitral valve is normal in structure and mobility. Normal flow through both the RVOT and LVOT. Trivial TR. No AI or PI. No pleural or pericardial effusion seen. No obvious cardiac tumors.

CARDIAC CHART

FELINE CARDIAC PARAMETERS	BODY WEIGHT (kg)	HR (BPM)	IVSd (cm) (Moise, Pipers)	LVIDd (cm) (Moise, Pipers)	LWVd (cm) (Moise, Pipers)	FS (%)	EF (%)
NORMAL PARAMETER	-----	150-240	0.35-0.55	<2 (mean 1.5)	3.5-0.55	35-67	80-100
PATIENT	3.8	240	0.44	1.6	0.44	40	76
FELINE CARDIAC PARAMETERS	LA/AO (Boon)	LA/AO HEART BASE (Swe) (Abbott)	LA 2D short axis Base view (cm) (Abbott)		LVOT VEL (m/s)	RVOT VEL (m/s)	E max (m/s)
NORMAL	<1.5	<1.3	<1.2		<1.6	<1.3	<0.9
PATIENT	NM	1.2	1.1		0.9	1.0	NM

**Note: All measurements based upon multi-modal images and methods. An average value is reported.*
Adapted from June Boon, Veterinary Echocardiography, 1998
Abbott J & MacLean H JVIM 2006;20: 111-119, Moise et al. Am J Vet Res 47:1476, 1986. Pipers et al. Am J Vet Res 40:882, 1979.

INTERPRETATION OF THE FINDINGS & FURTHER RECOMMENDATIONS

Overtly normal cardiac structure and function. The LV wall thickness is normal and there is no evidence of elevated left atrial pressure. No obvious congenital issues are documented.

Given these findings, no medications are indicated. It is important to note that phenotypic HCM can develop at any phase of life in cats (particularly in this predisposed breed), and often does not accompany a heart murmur or PE abnormalities. Periodic screening is ideally recommended in all cats.

No cardiac contraindication for breeding or general anesthesia at this time.

Recommend recheck echocardiogram in 1 year to assess for development of disease, sooner if a murmur/gallop or clinical signs develop in the interim.

IMAGING PERFORMED BY

svsmobileimaging.com 309-737-3070



Clinical Sonography & Telecytology

EDUCATIONAL TELECONSULTATION SERVICES™

1-800-838-4268 info@sonopath.com SonoPath.com

PATIENT

Jules Hudson

SPECIES

Feline

BREED

Sphynx

SEX

Female Intact

AGE

5 years

WEIGHT

8.4lbs

INTERPRETED BY

Maggie Machen Lamy, DVM, DACVIM (Cardiology)

IMAGING PERFORMED BY

Sarah Pender, CVT

HOSPITAL NAME

SVS Imaging QC

REFERRING VET

Dr. Narske

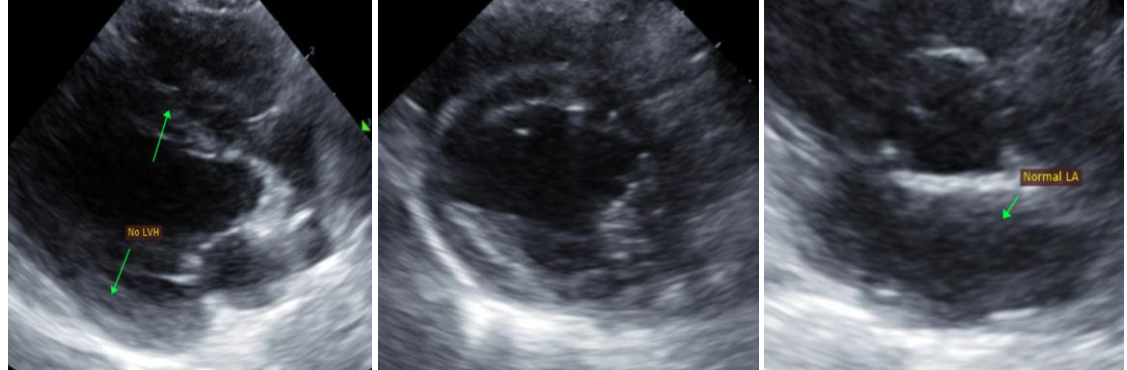
INVOICE

29783

DATE

3/22/23

IMAGES



The information and recommendations provided are based on the images presented by the referring veterinarian. No evaluation can be communicated regarding pathology that was not visible in the image/video clips provided.

Thank you for this referral. If the clinical or image interpretation does not parallel your findings or if I can be of any further assistance, please contact me.

Maggie Machen Lamy, DVM
Diplomate of the American College of Veterinary Internal Medicine (Cardiology)
info@sonopath.com